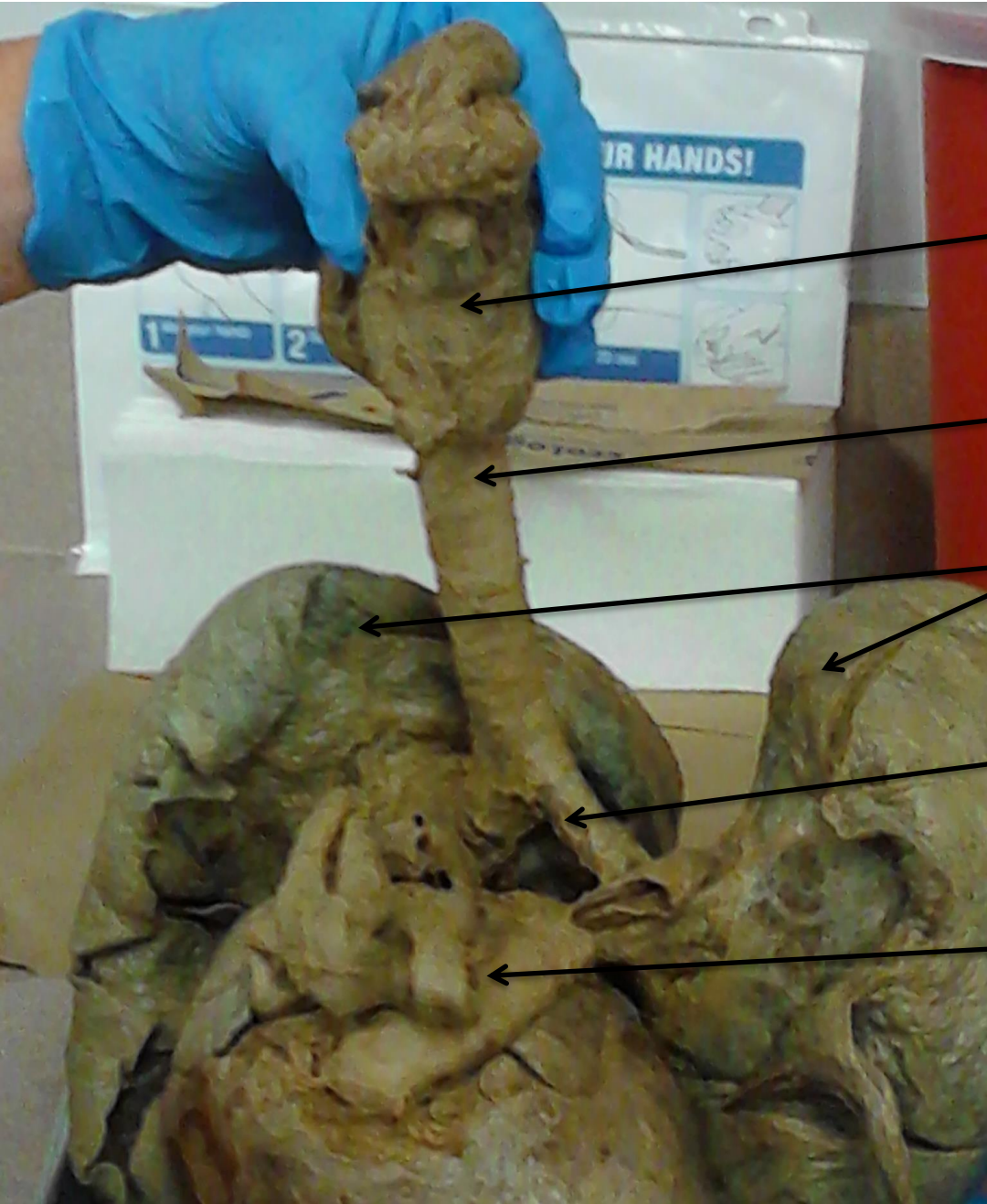



Larynx

Trachea

Lungs

Primary Bronchi

Pulmonary trunk

Grater curvature

Pylorus

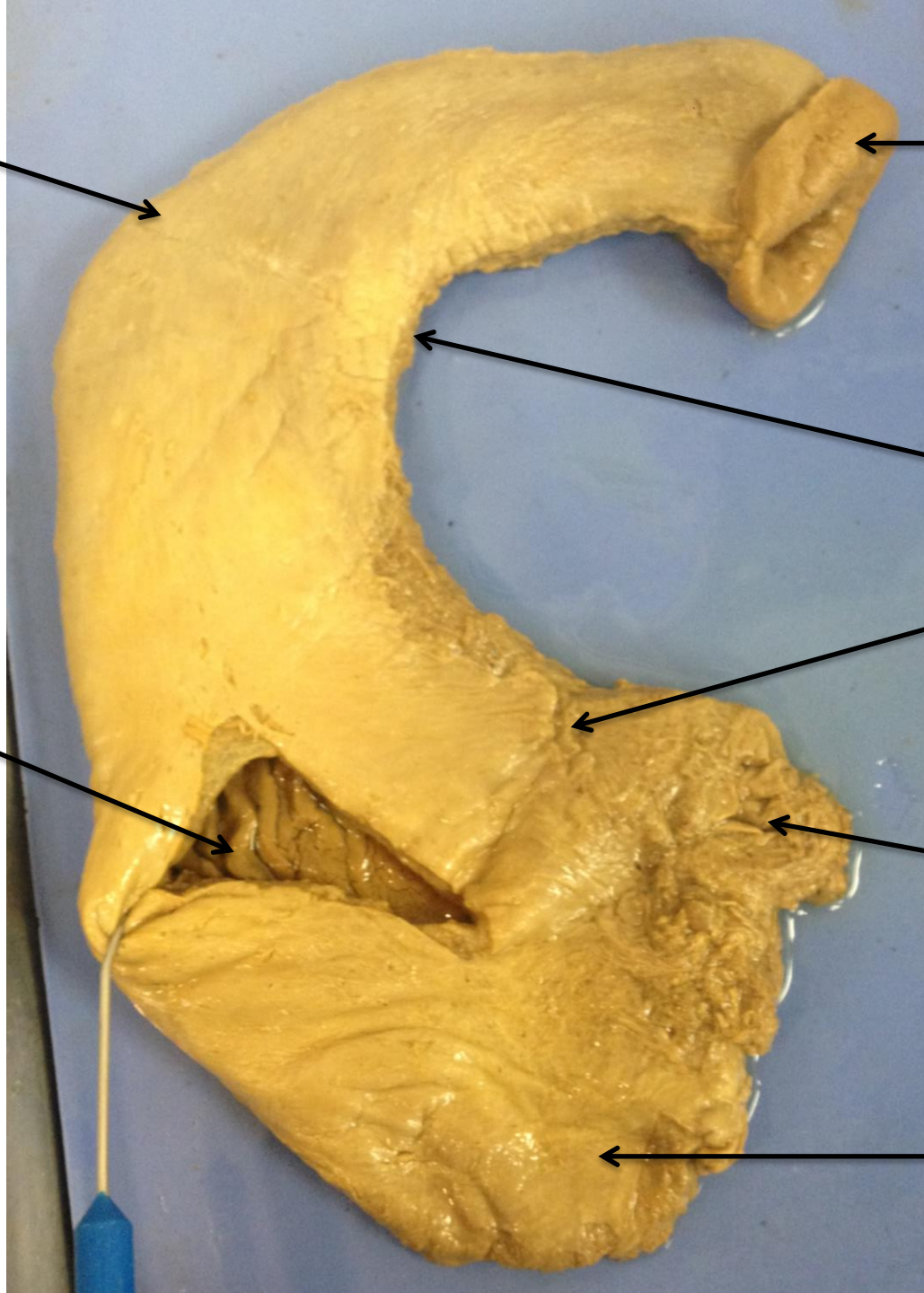
Lesser curvature

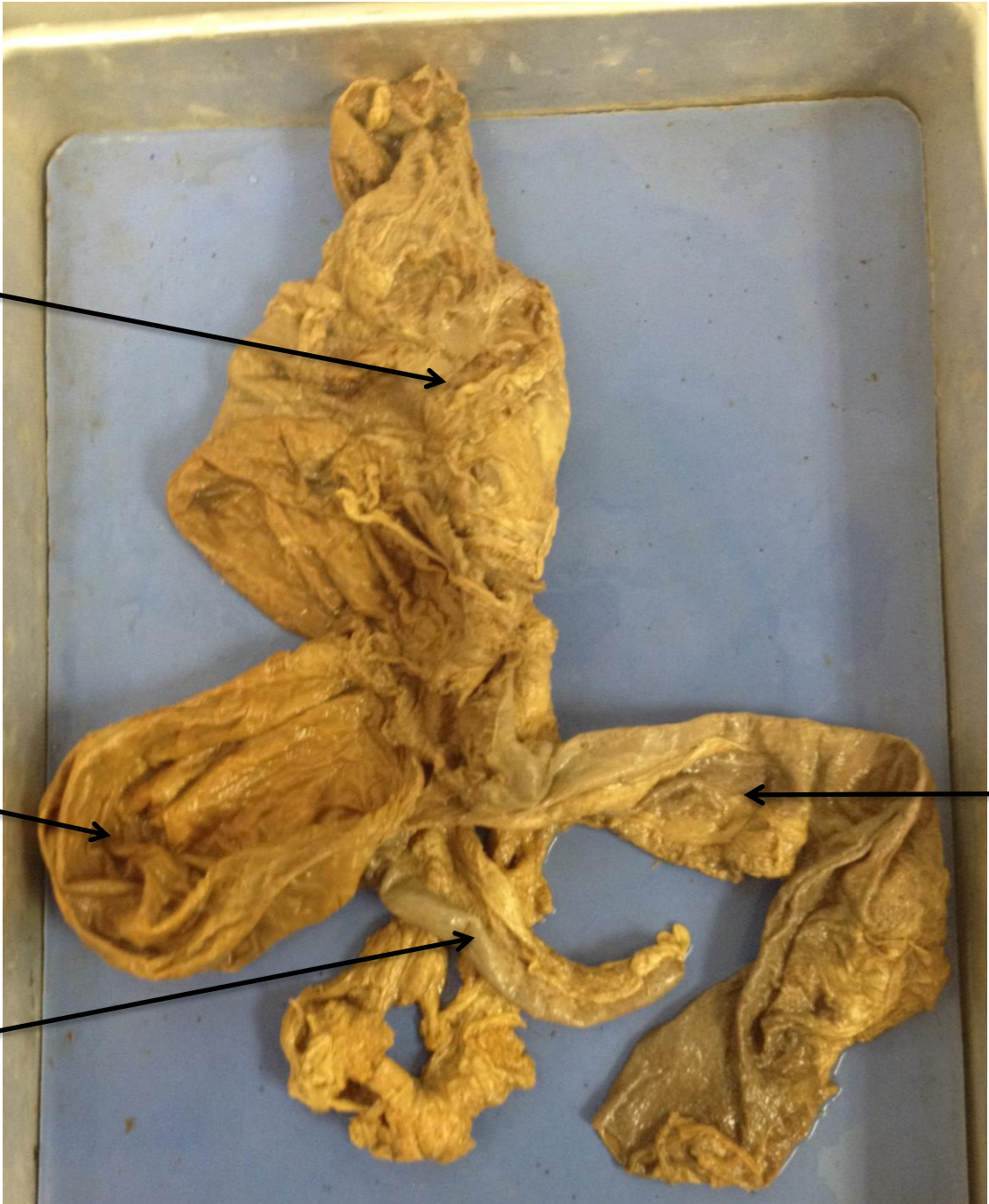Cardiac region

Rugae

Gastroesophageal  
sphincter

Fundus





Ascending colon



Cecum

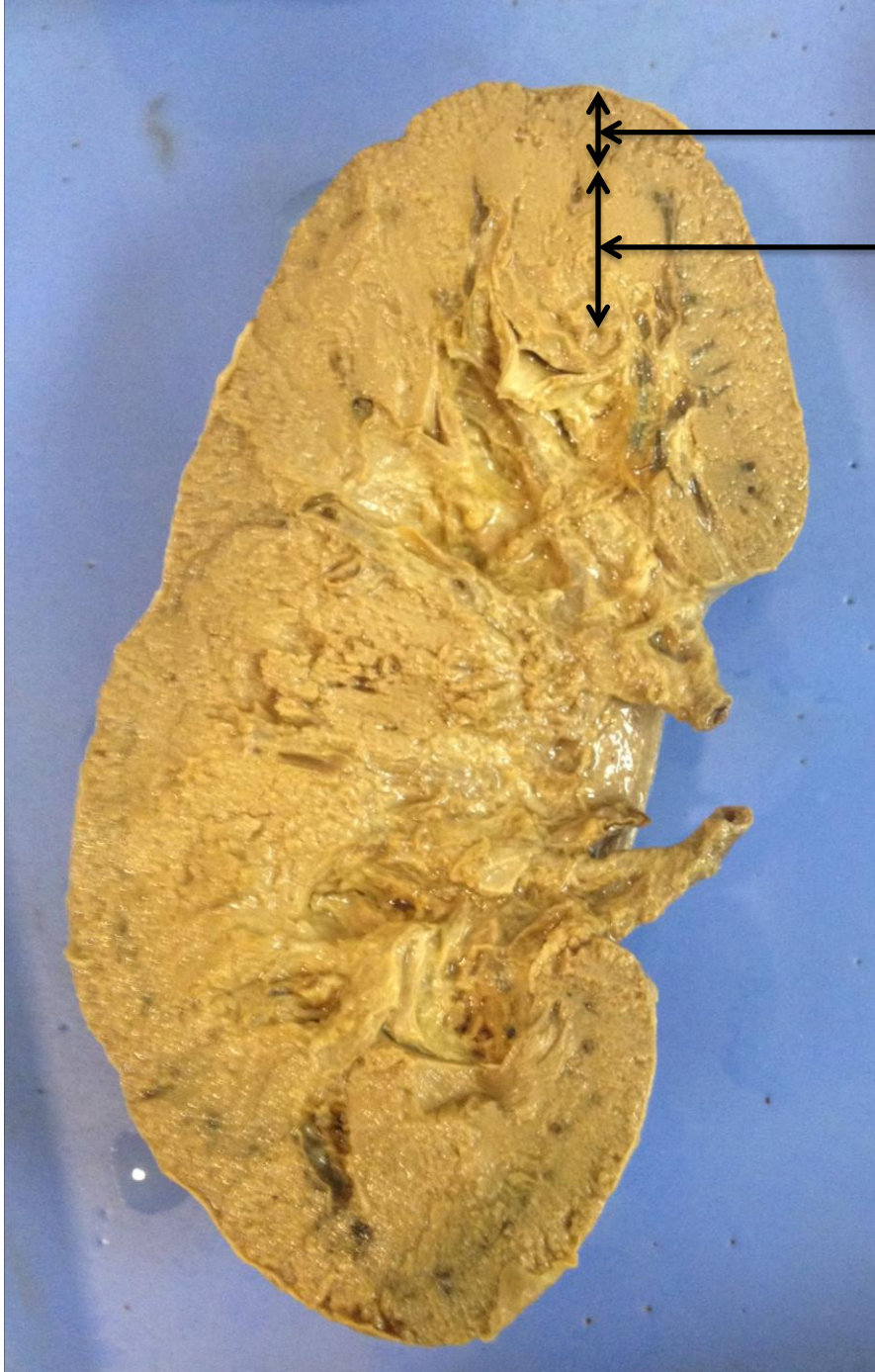

Ileum



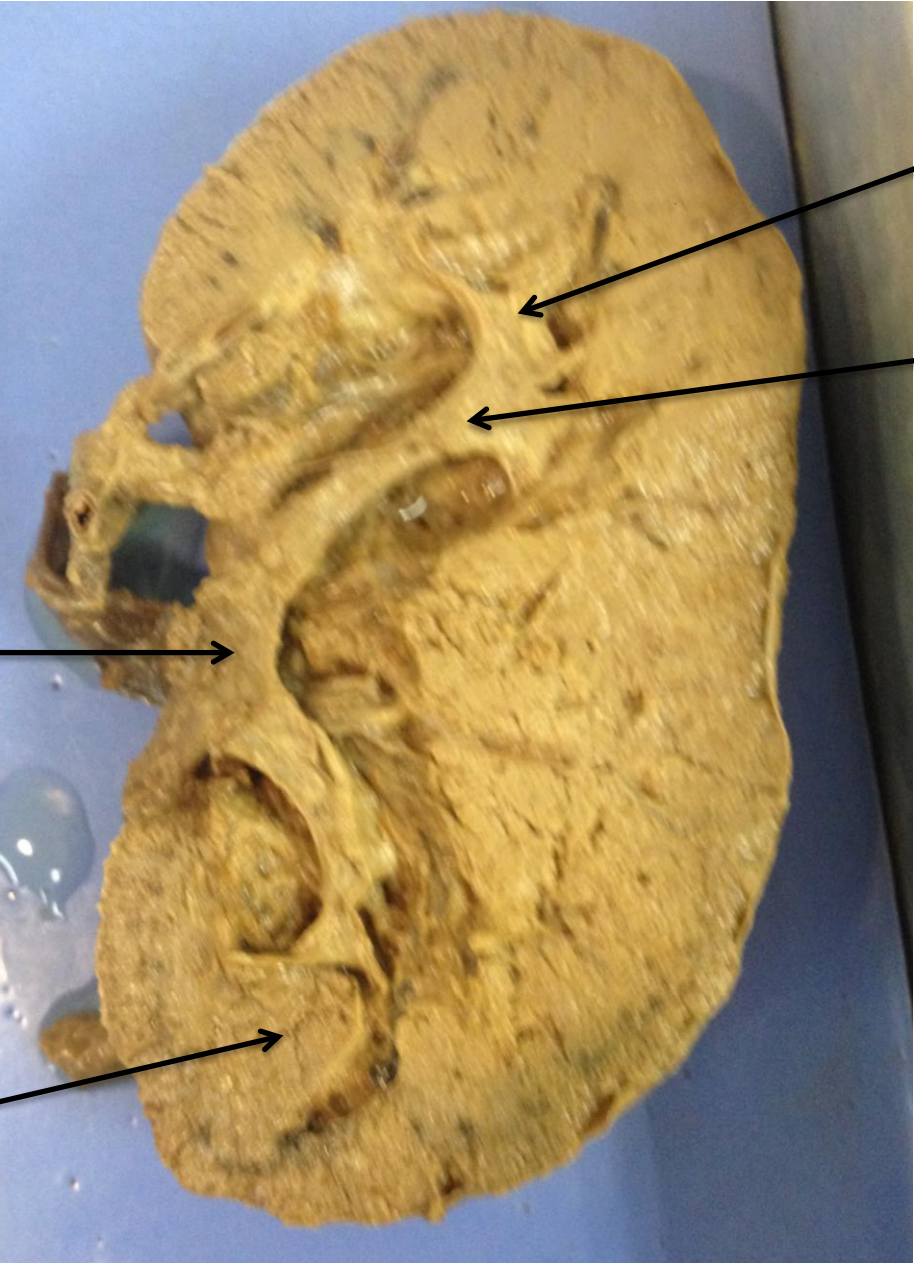Appendix





Cortex

Medulla

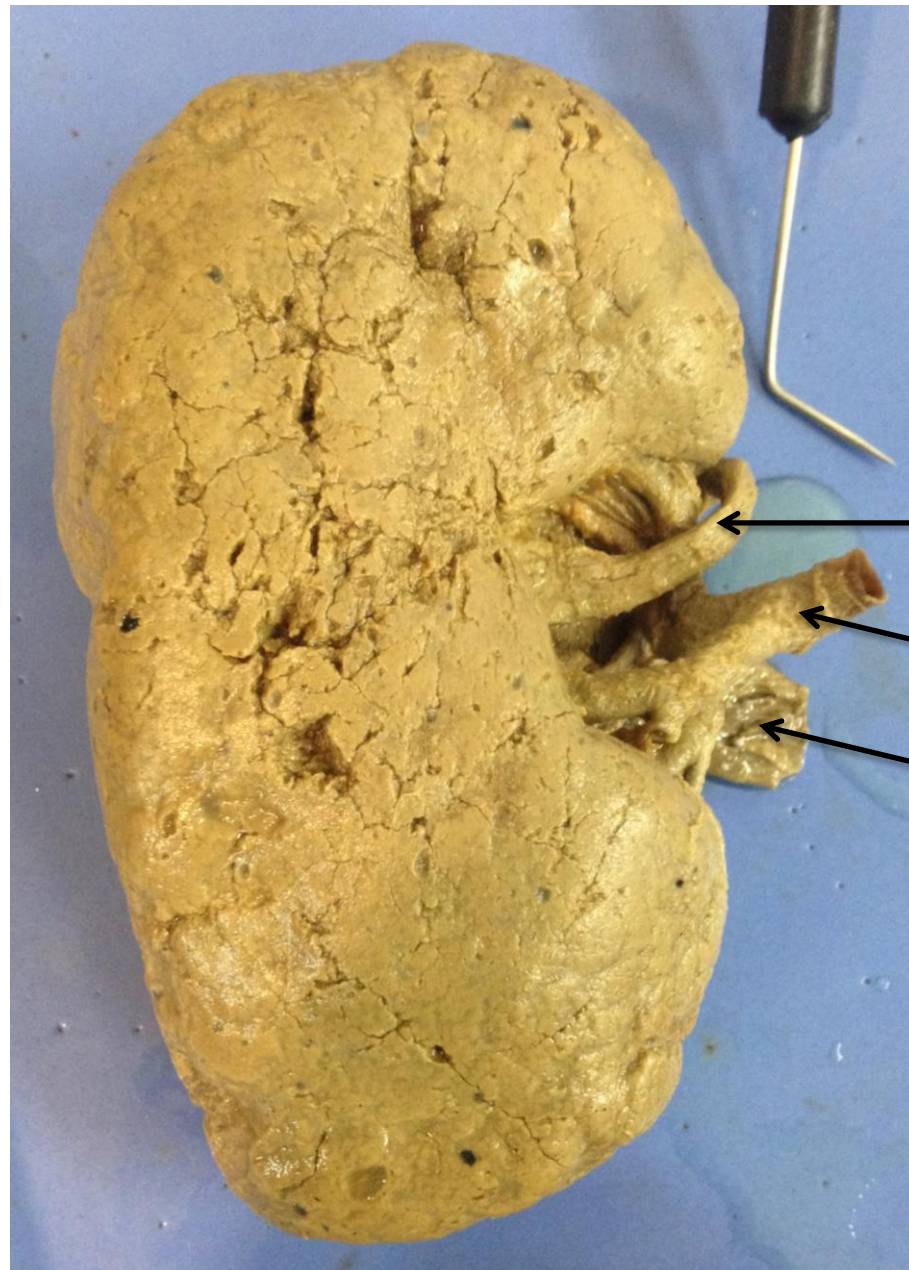

Minor Calyx

Major Calyx

Renal pelvis

Medullary pyramid



Ureter

Renal artery

Renal vein